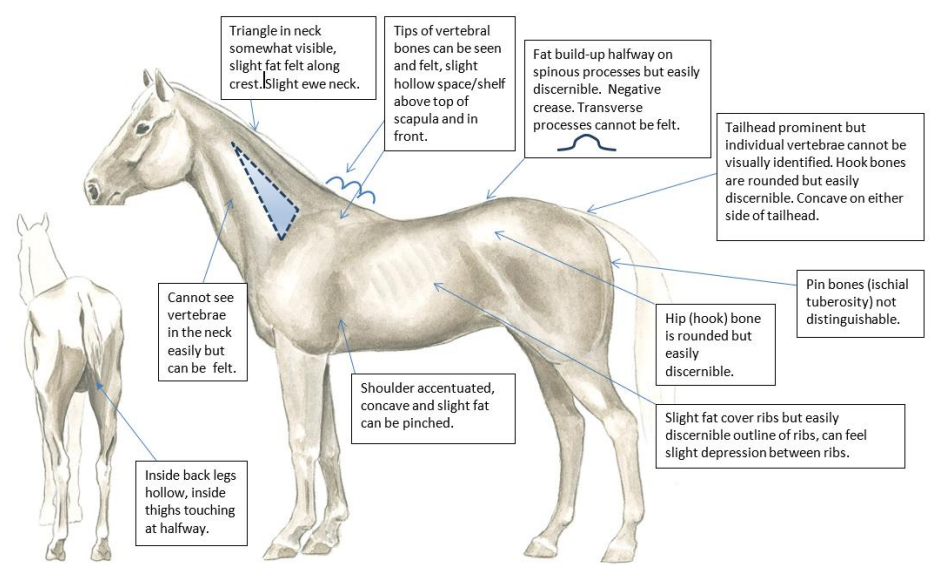
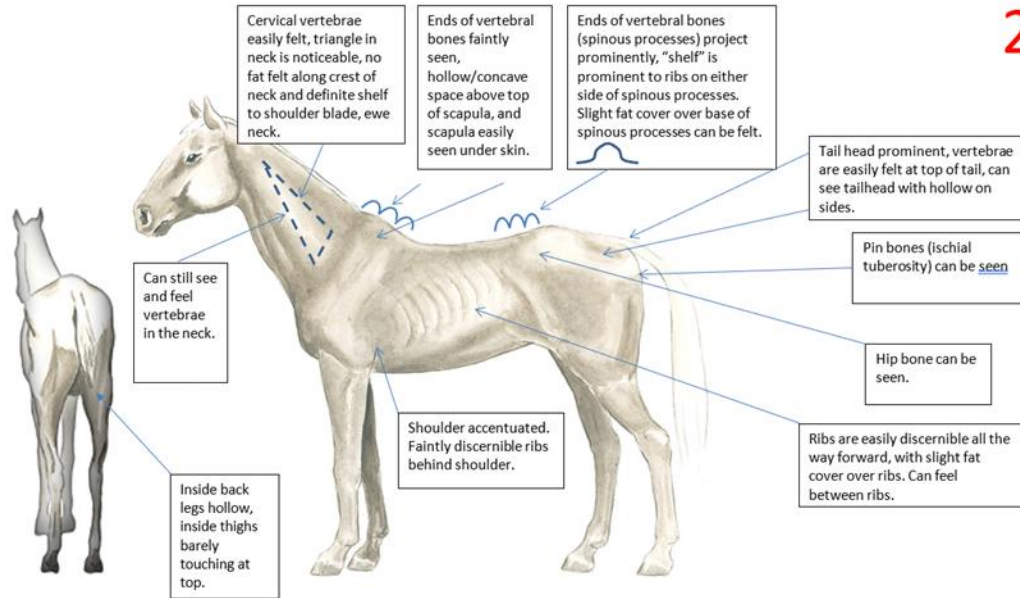
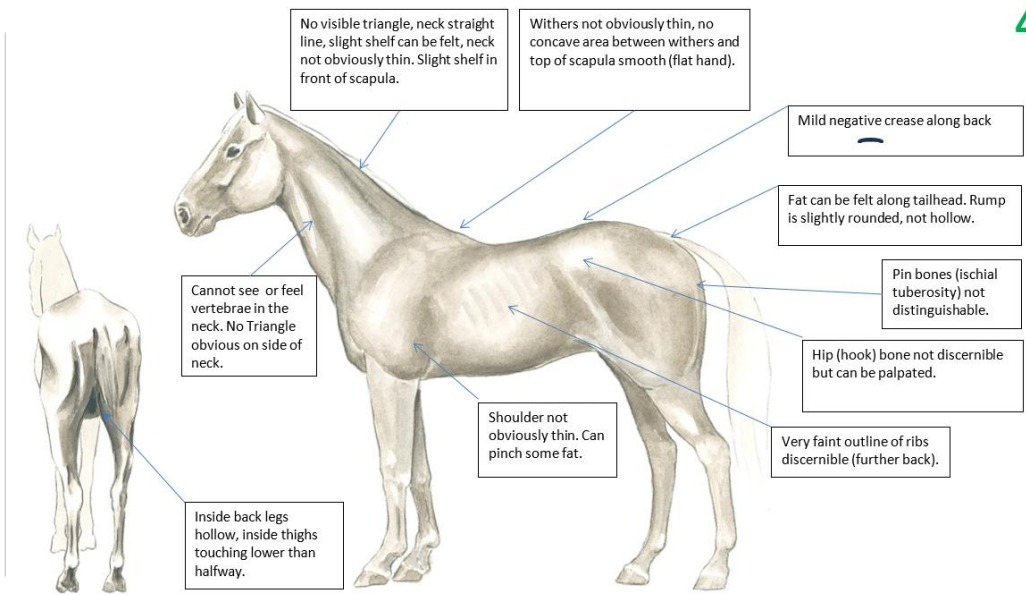
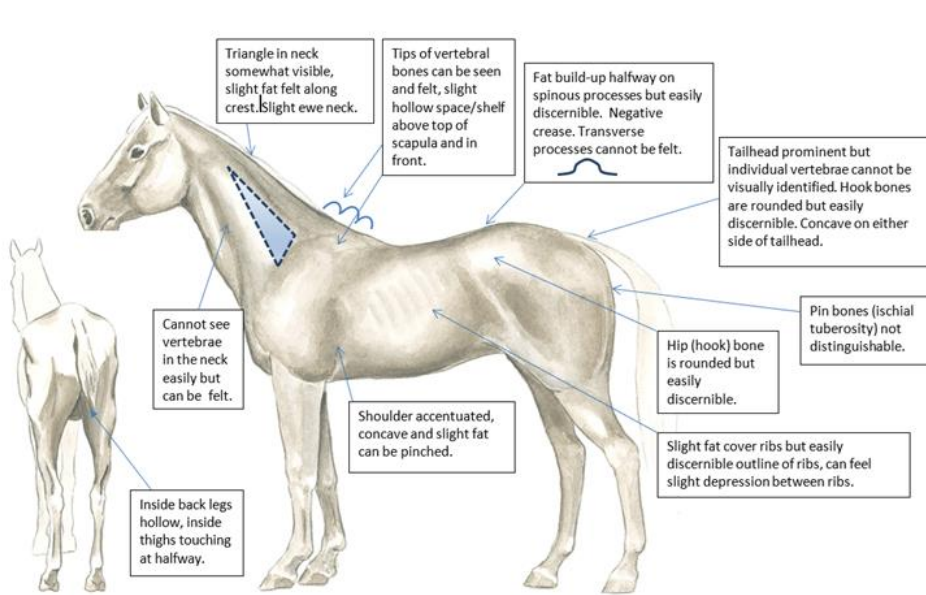


2



Condition	Neck	Withers	Loin	Tailhead	Ribs	Shoulder
2 Very Thin	Cervical vertebrae easily felt/faintly discernible, animal emaciated	Faintly discernible, concave above top of scapula	Slight fat covering over base of spinous processes. Transverse processes of lumbar vertebrae feel rounded. Spinous processes are prominent.	Tailhead prominent, can feel vertebrae in tail	Slight fat cover over ribs. Ribs easily discernible.	Shoulder accentuated
3 Thin	Neck accentuated	Withers accentuated	Fat buildup halfway on spinous processes but easily discernible. Transverse processes cannot be felt.	Tailhead prominent but individual vertebrae cannot be visually identified. Hook bones appear rounded but are still easily discernible. Pin bones not distinguishable.	Slight fat cover over ribs. Individual ribs easily discernible and palpable	Shoulder accentuated



Condition	Neck	Withers	Loin	Tailhead	Ribs	Shoulder
3 Thin	Neck accentuated	Withers accentuated, can see tips of vertebrae	Fat buildup halfway on spinous processes but easily discernible. Transverse processes cannot be felt.	Tailhead prominent, individual vertebrae cannot be visually identified. Hook bones appear rounded but are still easily discernible. Pin bones not distinguishable.	Slight fat cover over ribs. Ribs easily discernible visually and a bit through fingers	Shoulder accentuated, concave with slight fat pinch.
4 Moderately Thin	Neck not obviously thin. Neck is straight line from withers to bottom of ears, no triangle in neck	Withers not obviously thin, flat hand over top of scapula	Mild negative crease along back	Prominence depends on conformation; fat can be felt. Hook bones not discernible.	Faint outline discernible	Shoulder not obviously thin